

### Use of PRF & PRP in ENT Practice- An Observational study

Dr. Vikrant Dagar<sup>1</sup>, Dr. Gajanan Mohniraj Kashid<sup>1</sup>,  
Dr. Shaziya Pathan<sup>2</sup>, Dr. Ashok Gaikwad<sup>1</sup>, Dr.  
Harsala Palve<sup>3</sup>, Dr. Amit Gupta<sup>2</sup>

<sup>1</sup>Consultant, <sup>2</sup>Resident, <sup>3</sup>Anesthesiologist,  
Gajanan ENT Hospital, Ahmednagar-414001

Corresponding Author : Dr. Gajanan Mohniraj Kashid  
E-mail : entgajanan@gmail.com

Address : Gajanan ENT Hospital, Ahmednagar-  
414001 Ph No.- 09421588905

#### Abstract :

**Background:** Platelet rich plasma (PRP) & Platelet rich fibrin (PRF) plays important role in wound healing. Those raised my interest to assess the use of PRP & PRF in ENT to assess its effect on wound healing. PRP Injection used in Reducing Facial scar, Postoperative scar, Intratympanic Injection for sudden sensorineural hearing loss (SNHL). PRF used in Rhinoplasty for smooth nasal dorsum & less postoperative oedema and for mastoid obliteration to reduce post-operative infections and also used to close post-operated skull base defects. Aim: The purpose of this study to validate enhanced healing effect of PRF & PRP therapy in ENT. **Methodology:** PRP & PRF were prepared with 10cc venous blood of patient with help of centrifugal machine. PRP Injection given in patients with Facial scar, Sudden SNHL, Postoperative scar. PRF used in Rhinoplasty, mastoid obliteration & Post-operated skull base defect. Patients were assessed by examining the effect of PRP Injection & postoperative result after using PRF. Result: We have noticed Less postoperative odema, scarring, infection and improvement in SNHL. **Conclusion:** Although our findings were short-term in our study, but we found there is a significant improvement in Postoperative oedema, Infection & Scarring

**Keywords:** Platelet Rich Plasma (PRP), Platelet Rich Fibrin (PRF), Platelet Rich Fibrin Matrix (PRFM)

#### Introduction :

PRF & PRP increases the platelets in wound area by 2-3

times which increases the amount of Growth factors that help in promoting wound healing.<sup>(1,2)</sup> Thromboplastin is released from activated platelets. Thromboplastin converted into thrombin by activation of prothrombin, Thrombin converts fibrinogen into fibrin which form clot plug in bleeding area. The fibrin network captures circulating root cells and activates vascularization in the wound area. It has been found that the fibrin matrix directly activates angiogenesis.<sup>(3)</sup> PRF is also commonly used in surgical procedures Maxillofacial surgery, Spinal surgery, Cardiac bypass surgery, Angiogenesis procedures, Rotation and transposition of flaps, Macular lesions, Corneal epithelial defects.<sup>(4)</sup> Application of PRF matrix in septo-rhinoplasty shows improvement in terms of nasal dorsum irregularities and nasal edema.<sup>(5)</sup> PRP injections used in Acne scar<sup>(6)</sup>, Postoperative scar, Intratympanic Injection in sudden SNHL. Platelet-rich fibrin (PRF) is developed and published by Choukroun in 2001.<sup>(7)</sup>

#### Methodology :

##### Aim:

1. The purpose of this study to validate enhanced healing effect of PRF & PRP therapy in ENT
2. To Investigate the success of Platelet-rich fibrin matrix (PRFM) in septo-rhinoplasty to reduce Nasal dorsum irregularities & oedema.
3. To Investigate the success of Platelet-rich plasma in reducing postoperative scar, Acne scars & Sudden SNHL.

It was an Observational study. Patients were selected from ENT outpatient department in Gajanan ENT Hospital, Ahmednagar (MS). Written and informed consent were taken. The study was of 6 month duration from June 2019 to November 2019. Patient suffering from Acne scar, Postoperative scar, Sudden SNHL were given PRP Injection. In Acne scar and Postoperative scar PRP Injection given locally in subdermal region with 1ml syringe while in sudden SNHL given Intratympanic 0.5 to 0.9 ml near Round window with help of Spinal needle. PRF matrix wrapped cartilage used in Septo-rhinoplasty patients and mastoid obliteration and closing postoperative skull base defects.

PRF matrix preparation- Intra-operative 10cc venous blood was taken into two separate biochemistry tubes Centrifuged at 3000 rpm for 12 minutes PRFM was prepared.<sup>(8)</sup> PRFM kept Standing for 70 minutes.



Fig 1: Centrifugation Machine

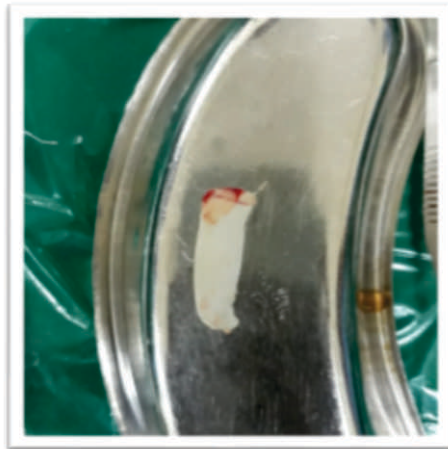

Fig 2: Platelet Rich Fibrin Matrix




Fig. 3 : Platelet Rich Plasma

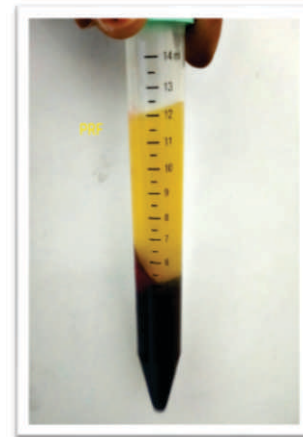


Fig. 4 : Platelet Rich Fibrin

**PRP preparation:** 10 cc venous blood was taken into two separate biochemistry tubes Centrifuged at 1500 rpm for 12 minutes PRP was prepared. Patients were followed for 3 months. Post-operated Oedema, nasal dorsum irregularities, Infection & scarring were observed. SNHL improvement were identified by Pure Tone Audiometry before intratympanic injection and after 7 days of PRP Injection.

**Results:**

16 patients suffering from Acne & Postoperative scar were injected PRP locally. Out of 16, 7 patients were suffering from Acne and 9 patients were suffering from postoperative scar. 5 patients of Acne and 7 patients of postoperative scar got relieved after 3 PRP local injections. 9 patients suffered from Sudden sensorineural hearing loss were injected intratympanic PRP, Out of 9 patients 5 patients got 40db improvement & 2 patients got 35db improvement and 2 patients got 24db improvement after 4 injections of PRP in every week.

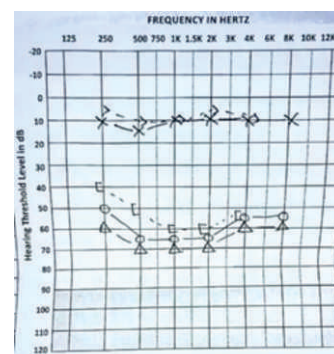


Fig 5: PTA Before PRP Injection

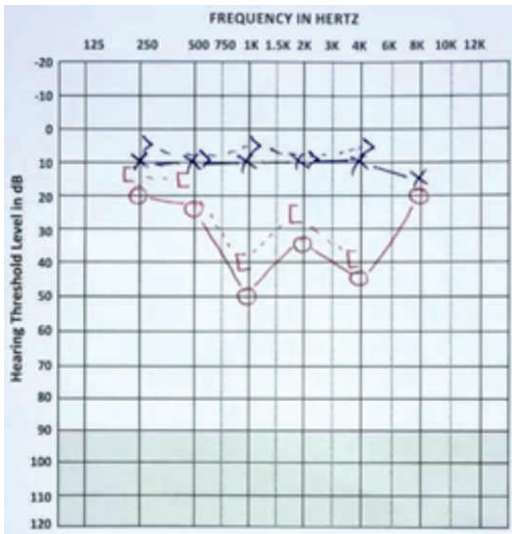


Fig 6: PTA After 2injections of PRP

Patients who came early got maximum benefit in hearing. 18 patients underwent septo-rhinoplasty, PRF matrix with sliced cartilage kept over nasal dorsum, Out of 18 patients , 3 patients got mild edema, 1 patient got mild nasal dorsum irregularity.

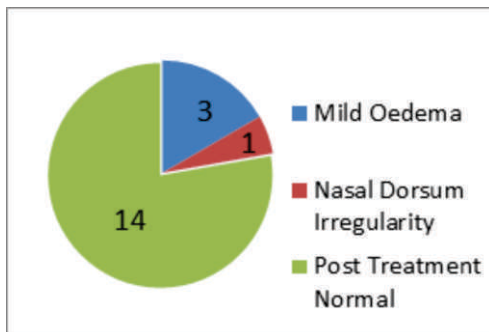


Fig 7: Outcome of Septo-rhinoplasty After using PRF matrix with cartilage

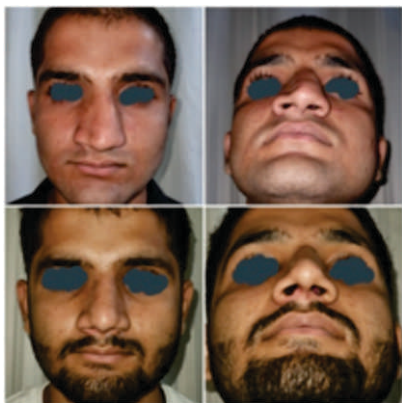

Fig 8: Pre and Post-operative Septo-rhinoplasty pics After Using PRF

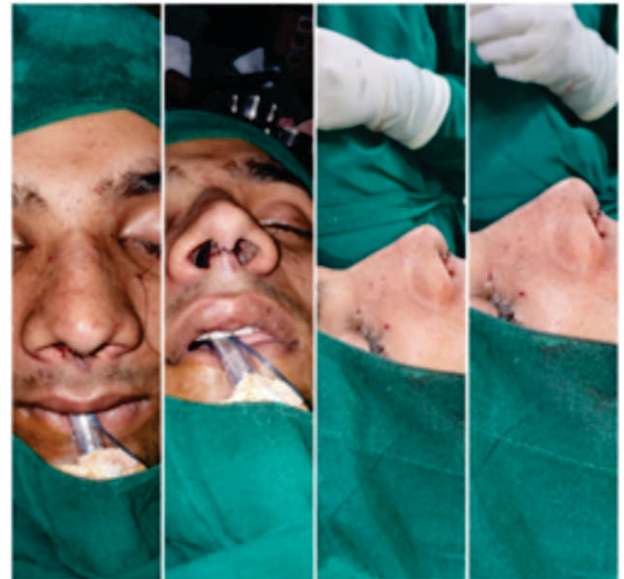

Fig 9: Post-operativeSeptorhinoplasty smooth nasal dorsum after using PRF

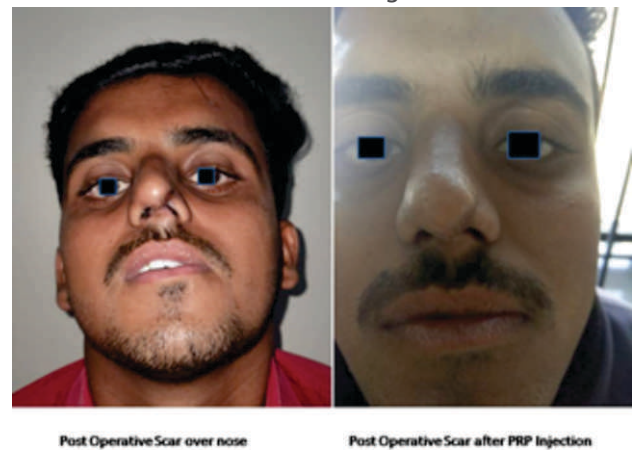


Fig 10: Postoperative scar over nose and Scar after 4 Local subdermal Injections of PRP

22 Mastoid cavity obliteration done with PRF matrix with sliced cartilage and muscle, out of 22 , 1 infected mastoid cavity was seen postoperatively during 2nd month follow up. In 4 cases of postoperative skull base tumour PRF matrix was used along with fascia and fat to close the skull base defect.

**Discussion:**

Although our findings were short-term in our study, but we observed there was a significant improvement in Postoperative Oedema & Infection in postoperative septo-rhinoplasty patients and mastoid obliteration patients and skull base defect closure patients.

Improvement also seen in Nasal Dorsum irregularities after septo-rhinoplasty. We also noticed improvement in Acne scar, Postoperative scar and Hearing in Sudden SNHL patients after PRP Injections. Out of 7 patients of Acne 2 patients not improved and out of 9 patients of postoperative scar 2 not improved might be due to atrophic scar. Out of 22 mastoid cavity 1 cavity was found infected might be due to hidden cholesteatoma.

#### Conclusion:

PRP & PRF are cost effective tools can be used in future for ENT practice in certain disease for better outcome. Definitely this study included a small sample size, which is a limitation. Future suggestions would be to include larger sample size and randomization to decrease bias.

#### References :

1. Pierce G F, Mustoe T A, Altrock B W, Deuel T F, Thomason A (1991) Role of platelet-derived growth factor in wound healing. *J Cell Biochem* 45: 319-326.
2. Nurden AT, Nurden P, Sanchez M, Andia I, Anitua E (2008) Platelets and wound healing. *Front Biosci* 13: 3532-3548.
3. Choukroun J, Diss A, Simonpieri A, Girard MO, Schoeffler C, Dohan SL, et al. Platelet-rich fibrin (PRF): a second-generation platelet concentrate. Part V: histologic evaluations of PRF effects on bone allograft maturation in sinus lift. *Oral surgery, oral medicine, oral pathology, oral radiology, and endodontics*. 2006 Mar;101(3):299-303. PubMed PMID: 16504861.
4. Bhanot S, Alex JC. Current applications of platelet gels in facial plastic surgery. *Facial plastic surgery*. 2002;18(1):27-34.
5. Ismail Guler<sup>1</sup>, Rauf Oguzhan Kum<sup>2</sup>, Yavuz Fuat Yilmaz<sup>3</sup>, *ENT Updates* 2019;9(1): 53-58.
6. Anthony P. Scalfani, Applications of Platelet-Rich Fibrin Matrix in Facial Plastic Surgery, *Facial Plast Surg* 2009;25:272.
7. Choukroun J, Adda F, Schoeffler C, Vervelle A. Une opportunit?? en paro-implantologie: Le PRF2001. 55-62 p.
8. Ismail Guler, Rauf Oguzhan Kum, Yavuz Fuat Yilmaz, *ENT Updates* 2019;9(1): 54.