

## Chemical Injury to Eye- A case report

**Dr. Sneha Murade<sup>1</sup>, Dr. Sonali Biradar<sup>2</sup>, Dr. Pooja Waghmare<sup>3</sup>**

<sup>1</sup>Assistant professor, <sup>2</sup>Senior Resident, <sup>3</sup>Junior Resident, Department of Ophthalmology, DVVPF's Medical College & Hospital, Ahmednagar-414111, Maharashtra, India

### Abstract:

Chemical burns represent blinding ocular injuries and constitute an ocular emergency requiring immediate assessment and initiation of treatment. The majority of patients are of young age groups and exposure will occur anywhere as an accident and in association with criminal assaults too. Alkali injuries occur more frequently. Chemical injuries of the eye produce extensive damage to the conjunctiva, cornea, anterior segment and limbal stem cells resulting in unilateral or bilateral visual impairment. This article reviews the emergency management to improve the prognosis of patients with chemical injuries.

**Keywords:** Acid, Alkali, Chemical burns, Ocular Injuries

### Introduction:

Chemical ocular burns comprise 5.5–15.5% of all ocular trauma cases in various parts of the world.[1,2] It is inevitable for an ophthalmologist to be consulted for an acute chemical burn.[3] Chemical ocular burns can be caused by agents of acidic (low pH) or alkaline (high pH).[4-6]

Alkaline substance is lipophilic in nature and causes saponification and hence deeper penetration. Acidic substance, on the other hand, leads to protein denaturation and barrier formation that inhibit deeper penetration. Thus, alkaline chemical injury is more dangerous.[7] After chemical exposure, patients often complain of moderate to severe pain, photophobia, blurred vision, and sensation of a foreign body. Reflex blepharospasm and red eye are common signs of chemical injury.[8] Following an ocular burn, the disease process has several stages that require specialist ophthalmology-led treatment focusing on each stage of disease process.[9]

### Case Report:

11-year-old male child brought by his parents in casualty with the history of mobile battery explosion. The glass and other material splashed in his right eye while playing with the battery. He complained of swelling in right eye and was unable to open the right eye with severe eye pain.

**Corresponding Author:** Dr. Sneha Murade

**Email ID:** snehamurade@gmail.com

**Address:** Department of Ophthalmology, DVVPF's Medical College & Hospital, Ahmednagar-414111, Maharashtra, India

Patient's detailed history was recorded from parents regarding the exposure to the chemical. On ophthalmic examination his visual acuity - Right eye 6/60 and of left eye 6/6.

Torch light and slit lamp examination were performed. The right eye showed lid edema, conjunctival and circumcorneal congestion. First degree burn injury in upper and lower eye lid. Cornea showed total corneal epithelial defect with corneal stromal haze. On staining with 1% Fluorescein and observing under cobalt blue filter a total corneal epithelial defect was noted. There was limbal ischaemia from 6 to 9 o'clock. Rest anterior segment details of the right eye were not appreciable. Examination of the left eye was unremarkable. Digital palpation approximated normal bilateral IOP. Moderate haze with less than 1/3 of perilimbal ischemia, grade 2 chemical burn with ROPER HALL classification is diagnosed.

### Roper Hall classification.

Roper-Hall Classification System			
Grade	Prognosis	Limbal Ischemia	Corneal Involvement
I	Good	None	Epithelial damage
II	Good	<1/3	Haze, but iris details visible
III	Guarded	1/3 to 1/2	Total epithelial loss with haze that obscures iris details
IV	Poor	>1/2	Cornea opaque with iris and pupil obscured

**ISSN No. :** (p) 2348-523X, (o) 2454-1982

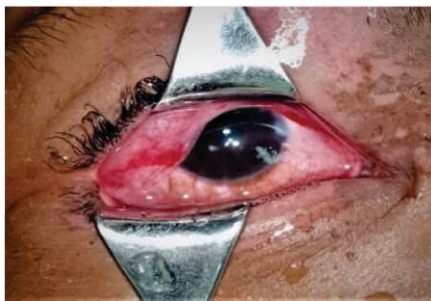**DOI:** 10.46858/vimshsj.8408

**Date of Published :** 31<sup>th</sup> December 2021

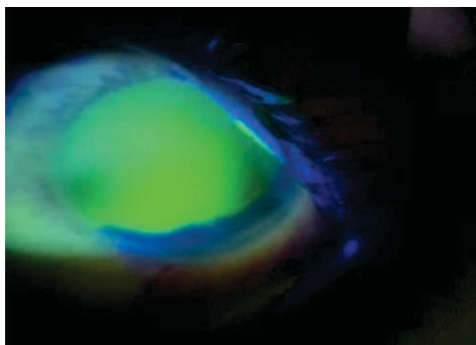
Grade 4 chemical burn according to DUAS classification with 6 to 9 clock hours of limbal involvement with 50 to 75 % conjunctival involvement.

#### DUAS CLASSIFICATION

Gr	Prognosis	Clinical findings(clock hrs of limbal involvement)	Conjunctival involvement	Analogue scale
I	Very good	0 clock hours	0%	0.0%
II	Good	<3 clock hours	<30%	0.1-3/1-30%
III	Good	>3-6 clock hours	>30-50%	3.1-6/31-50%
IV	Good to guarded	>6-9 clock hours	>50-75%	6.1-9/51-75%
V	Guarded to poor	>9-<12 Clock hours	>75-<100%	9.1-11.9/75.1-99.9%
VI	Very poor	12 clock hours involved	Total conjunctiva (100%) involved	12/100%



**Image 1:** Affected eye (Right) showing circumcorneal congestion, chemosis, corneal edema



**Image 2:** Total corneal epithelial defect staining positive with Fluorescein examined under blue filter. This patient underwent initial management with 500 ml RL solution irrigation in the right side using a 10cc syringe. He was started on Tobramycin eyedrop 1 drop 6 times daily, tapering dose of Prednisolone eyedrop, carboxymethylcellulose eye drop 6 times a day, Oral Tablet Vitamin C 500 mg 3 times a day, ciprofloxacin 500 mg twice daily, and mefenamic acid 500 mg.

#### Discussion:

Ocular chemical injury is considered an emergency, thus urging timely and accurate management. The

injury it imposes depends on several factors, namely substance strength in acidity or alkaline property, amount or dose, and exposure duration.

The patient experienced diminution of vision, redness, and watering in the right eye. Sudden decrease in visual acuity could be contributed by corneal epithelial defect, stromal haze, lacrimation, or discomfort. In addition to diminution of vision, photophobia resulted from iris inflammatory contraction in which iris blood vessel dilatation occurred as a reflex response towards corneal nerve irritation.

Chemical injury to eye is managed with normal saline irrigation, oral and topical antibiotics administration, topical steroid, and artificial tears, with additional cycloplegic reserved for moderate to severe cases.[7]

Davis et al, evaluated patients with topical prednisolone 0.5% in conjunction with topical ascorbate 10% and concluded that there was not an associated increase in corneoscleral melt if topical steroids were used until reepithelization.[10]

Chemical burn injury can cause corneal opacity, melting of cornea, cataract and symblepharon. Symblepharon can be prevented by sweeping of ear bud coated with lubricant around upper and lower fornices.

#### Conclusion:

Chemical injury is a part of ocular emergencies requiring immediate and effective management. A chemical substance is warranted acid or alkali if the pH value measured below or over seven respectively. Alkali causes more severe damage than its acid counterparts for its

hydrophilic and lipophilic properties that allows rapid membrane penetration into the anterior chamber and even retina.

Classification system helps to navigate management strategy and prognosticate outcome. The importance of ocular irrigation is surmounted in prompt management plan. Supporting medications prescribed including antibiotics, steroid, and analgetics. Close follow up and diligent eye protective measures are vital in improving the outcome.

**References:**

1. Wagoner MD. Chemical injuries of the eye: current concepts in pathophysiology and therapy. *Survey of ophthalmology*. 1997 Jan 1;41(4):275-313.
2. Nicaeus T, Erb C, Rohrbach M, Thiel HJ. An analysis of 148 outpatient treated occupational accidents. *Klinische Monatsblätter für Augenheilkunde*. 1996 Oct 1;209(4):A7-11.
3. Soleimani M, Naderan M. Management strategies of ocular chemical burns: current perspectives. *Clinical Ophthalmology (Auckland, NZ)*. 2020;14:2687.
4. Herr RD, White GL, Jr., Bernhisel K, Mamalis N, Swanson E. Clinical comparison of ocular irrigation fluids following chemical injury. *Am J Emerg Med* 1991;9:228 31
5. Riordan-Eva P, Whitcher JP. Vaughan & Asbury *Oftalmologi Umum*. 17th ed. Jakarta: Penerbit Buku Kedokteran EGC; 2008.
6. Ilyas S. *Ilmu Penyakit Mata*. 5th ed. Jakarta: Fakultas Kedokteran Universitas Indonesia; 2014
7. Parul S, Manoj T, Yogesh K, Gupta KK, Sharma PD. Ocular chemical injuries and their management. *Oman J Ophthalmology*; 2013.
8. Pokhrel PK, Loftus SA. Ocular emergencies. *American family physician*. 2007 Sep 15;76(6):829-36.
9. Singh P, Tyagi M, Kumar Y, Gupta KK, Sharma PD. Ocular chemical injuries and their management. *Oman journal of ophthalmology*. 2013 May;6(2):83.
10. Davis AR, Ali QK, Aclimandos WA, Hunter PA. Topical steroid use in the treatment of ocular alkali burns. *Br J Ophthalmol*. 1997;81:732-4.