

Pterygium management and comparison of different surgical approaches with supportive treatment in Rural Maharashtra

Dr. Valay C. Parekh¹, Dr. Singh A. K.², Dr. Divate S. A.², Mr. Yash C. Parekh³

¹Junior Resident, ²Senior Resident, Department of Ophthalmology, DVVPFs Medical College & Hospital, Ahmednagar-414111, Maharashtra, India. ³IIIrd MBBS student, Jawaharlal Nehru Medical College, Datta Meghe Institute of Medical Sciences, Wardha-442107 Maharashtra, India.

Abstract:

Background: Numerous surgical procedures and changes have been ineffective in preventing the recurrence of pterygium. A prospective clinical observational analysis of 205 individuals with primary pterygium was conducted where patients were treated with various surgical procedures. The patients were observed for two to five years in order to examine the frequency of recurrences and consequences. Result: Patients were divided into four groups and treated using a variety of surgical methods. Straightforward excision of pterygium was the treatment of choice in group 1. Excision with conjunctival rotation pedicle graft was used on patients in Group 2. Excision and conjunctival autograft were used to treat Group 3 patients. Patients in Group 4 received excision and a 0.02 percent solution of mitomycin c drops as a postoperative treatment. Age varied from 22 to 58, with a median of 34. All four groups had an equal number of men and women. Hemorrhage, astigmatism, symblepheron, foreign body feeling, and a corneo-scleral ulcer were among complications that were reported. There were 12 percent complications in group 1, 16 percent complications in group 2, 6 percent complications in group 3, and 8 percent complications in group 4. Criteria for recurrence was defined as the regrowth of fibrovascular tissue or the appearance of an aesthetic flaw. It's 30 percent for group 1; 14 percent for group 2, 9 per cent for group 3, and 8 per cent for group 4. Conclusion: The least rate of recurrence was noted in patients of Group 4 who had pterygium excision with postoperative mitomycin c instillation, and complications were least common in patients in Group 3 who had pterygium resection with conjunctival autograft.

Keywords: Pterygium, Fleishy pterygia, Conjunctival autograft, Mitomycin C

Introduction:

Most common in tropical and subtropical environments, Pterygium, a triangular film of fibrovascular tissue that invades the cornea. Typically, the conjunctiva is the first place to show signs of the disease, which is caused by ultraviolet radiation (UV-B 320 nm to 286nm). A persistent inflammatory cellular infiltration with associated inflammatory oedema and cell-induced angiogenesis is seen histologically and epidemiologically in the case of pterygium, suggesting that Ultraviolet radiations play a role in its development.¹ Elastotic degradation of collagen and fibrovascular growth with an epithelial coating characterise the pathogenesis of pterygium.² The pathophysiology of

regrowth after surgical excision of primary pterygium differs from that of the initial disease. Pterygium removal has been attempted using a variety of surgical procedures and alterations, but none have been successful in preventing recurrence.³⁻⁹ Excision with autograft provides the benefit of putting limbal conjunctiva stem cells along the limbus of the necessary scleral bed when compared to other methods.¹⁰ In order to preserve the graft's blood supply, the limbal stem cells must be removed during resection using conjunctival rotation pedicle flap Mitomycin C is an anti-metabolite generated by *Streptomyces caespitosus*.⁴ Due of its propensity to suppress fibroblasts, it has been utilised as an additional therapy.^{3-5,11}

Corresponding Author: Dr. Valay C. Parekh

Email ID: valayparekh@gmail.com

Address: Department of Ophthalmology, DVVPFs Medical College & Hospital, Ahmednagar-414111, Maharashtra, India.

ISSN No. : (p) 2348-523X, (o) 2454-1982

DOI: 10.46858/vimshsj.9302

Date of Published : 30th September 2022

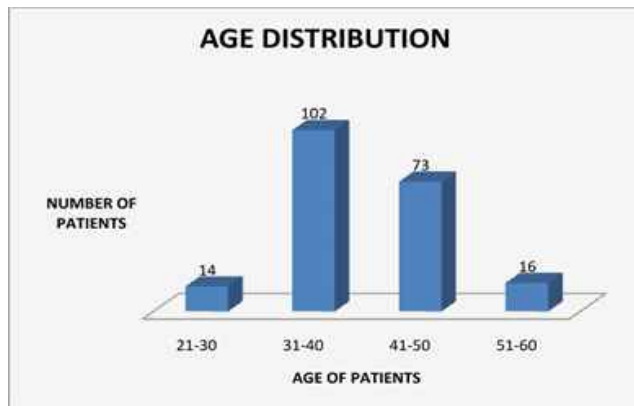
Methodology:

Aim of study: To investigate the recurrence rate of pterygium and the incidence of complications associated with surgery for pterygium in individuals who were treated for pterygium using various methods.

Slit lamps were used to evaluate patients with symptoms of primary pterygium. Fleshy pterygia required surgical intervention as it began to grow and cause symptoms. Four categories were used to categorise the treatments evaluated. Surgical excision in Group 1. A conjunctival rotation pedicle graft is used in Group 2 after excision. Conjunctival autograft in Group 3. In the fourth group, patients have excision followed by twice-daily instillations of mitomycin 0.02 percent for five days. We studied 205 individuals (331 eyes) with primary pterygia who were treated with one of these procedures and then tracked for 2-5 years. During follow-up visits, it was discovered that there were high rates of complications and occurrences. A few of the most common side effects were bleeding and foreign body feeling astigmatism.

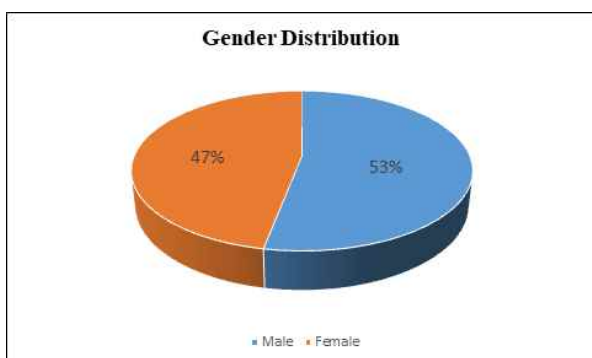
Results:

Fig 1: Distribution according to the age groups



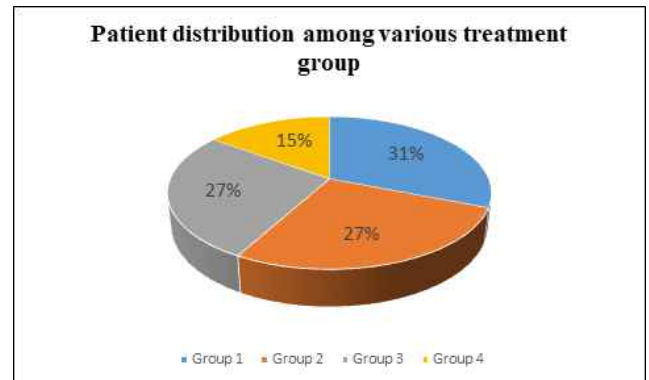
Patients spanned the age spectrum from 22 to 58 years. 102 of the 205 patients in the research were between the ages of 31 and 40, 73 were between the ages of 41 and 50, 16 were between the ages of 51 and 60, and 14 were between the ages of 21 and 30.

Fig 2: Distribution according to the Gender



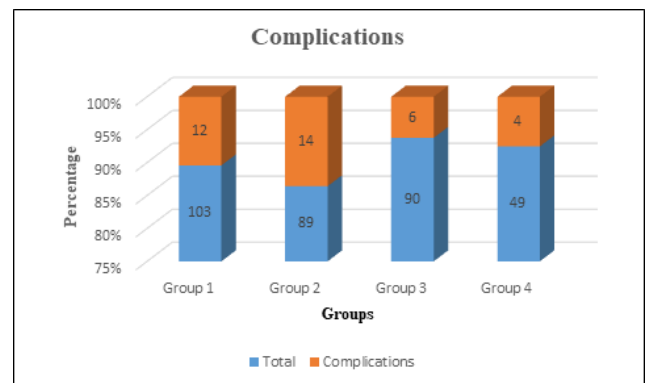
There were 109 male and 96 female patients, with a male to female ratio of 1:1.13.

Fig 3: Distribution of patients according to the treatment modality they went through



Group 1: Simple removal of the pterygium as treatment. Pterygium excision with conjunctival rotation pedicle graft is the treatment modality for Group 2. Excision of the pterygium with conjunctival autograft consisted of Group 3. Post-operative Mitomycin C 0.02 percent twice a day for 5 days is the treatment for pterygium excision in Group 4.

Fig 4: Complications in modality of treatment used



A total of 12 of the eyes in group 1 experienced complications. The most serious complications among them were haemorrhage and symblepharon.

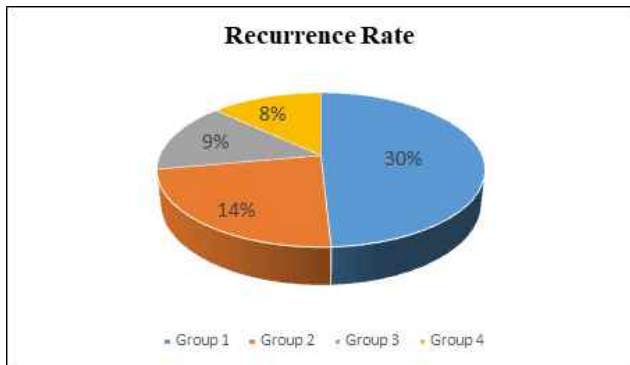
In the second group, 14 eyes were affected. Complications included haemorrhage, a foreign body perception, chemosis, and astigmatism.

Six eyes in group 3 reported complications. Haemorrhage and a foreign body perception were the most frequently reported side effects.

Four eyes in group 4 experienced problems. Patients had haemorrhages and one developed a corneoscleral ulcer.

Excision of pterygium with conjunctival autografting had lowest complications.

Fig 5: Recurrence Rate



Inference-The lowest recurrence rate of 8% was noted in excision with post-operative instillation of Mitomycin c.

Discussion:

A total of 205 of the 350 patients treated for primary pterygia were able to return for follow-up appointments. The research comprised 331 eyes from 205 participants. Over the course of the study, the patients were monitored for anything from two to five years. During follow-up visits, it was discovered that there were high rates of complications and occurrences.

Age ranged from 22 to 58, with most patients between the ages of 31 and 40 (Fig 1). Patients were on average 34 years old. Our research comprised 331 eyes from 109 male and 96 female participants (Fig 2).

A total of 103 patients were treated in the first group, 89 in the second, 90 in the third, and 49 in the fourth (Fig 3).

Complications that have been reported include bleeding, astigmatism, symblepharon, and corneoscleral ulcer. There were 12 percent complications in group 1, 16 percent complications in group 2, 6 percent complications in group 3, and 8 percent complications in group 4 (Fig 4) among the groups. With the conjunctival autograft, Group 3 had the lowest complication incidence.

Recurrence was classified as the regrowth of fibrovascular tissue or the appearance of an aesthetic flaw. The recurrence rate (Fig 5) in group 1 was 30%, group 2- 14%, group 3- 9%, and group 4- 8%. Pterygium excision with Mitomycin C infusion after surgery resulted in a low recurrence rate in Group 4. Conjunctival autograft and Minimally Invasive Pterygium Surgery were compared in a study by Bazzazi *et al.*, which found that patients treated with conjunctival autograft had an 11 percent recurrence rate.¹² In their research on intraoperative instillation

of Mitomycin C following pterygium also excision, Kareem A. A. *et al.* found an 8 percent recurrence rate with very minor sequelae.¹³ Both investigations show that pterygium excision with conjunctival autografts or intraoperative mitomycin C instillation has no severe consequences.

Conclusion:

Pterygium may be effectively and safely treated by instillation of mitomycin c post-operatively at modest doses and frequencies. Pterygium recurrence is typical after six months following surgery, although it may arise up to two decades later. A definitive judgement may only be rendered after a thorough examination of the cases over a period of 20 years.

References:

1. Anduze A. Pterygium. A Practical Guide to Management. New Delhi: Japee; 2009.
2. Garg Atoukhy E. Surgical and Medical Management of Pterygium. New Delhi: Jaypee; 2009:8-9
3. Jain AK, Bansal R, Sukhija J. Human amniotic membrane transplantation with fibrin glue management of primary pterygia: a new tuck in technique. *Cornea*. Jan 2008;27(1):94-9
4. Jiang J, Yang Y, Zhang M, Fu X, Bao X, Yao K. Comparison of fibrin sealant and sutures for conjunctival autograft fixation in pterygium surgery: one year follow up. *Ophthalmologica*. 2008;222(2):105-11
5. Garg Atoukhy E. Surgical and Medical Management of Pterygium. NEW DELHI: JAYPEE; 2009
6. Rocha, G.U.I.L.L.E.R.M.O., 2003. Surgical management of pterygium. *Tech Ophthalmol*, 1, pp.22-8.
7. Marcovich, A.L., Bahar, I., Srinivasan, S. and Slomovic, A.R., 2010. Surgical management of pterygium. *International ophthalmology clinics*, 50(3), pp.47-61.
8. Janson, B.J. and Sikder, S., 2014. Surgical management of pterygium. *The ocular surface*, 12(2), pp.112-119.
9. Assia, E., 2002. Surgical management of pterygium. *IMAJ-RAMAT GAN*, 4(12), pp.1138-1138.

10. Riordan-Eva, P., Kielhorn, I., Ficker, L.A., Steele, A.M. and Kirkness, C.M., 1993. Conjunctival autografting in the surgical management of pterygium. Eye-London-Ophthalmological Society of The United Kingdom Then Royal College of Ophthalmologists-,7, pp.634-634.
11. Anduze AL.Pterygium surgery with mitomycin –c:ten year results. Ophthalmic surg Lasers. 2001 ;32(4):341-5
12. Bazzazi N, Ramezani A, Rabiee M.A.S. A comparative study of conjunctival autograft and minimally invasive pterygium surgery in primary pterygia. Pakistan Journal of Biologic Science.2010;13/8:409-412.
13. Kareem A. A, Farhood Q.K., Alhammami H.A. Use of antimetabolites as adjunctive therapy in surgical treatment of pterygium. Clinical Ophthalmology. 2012;6/1(1849-1854).07 Nov 2012